



PATIENT

Koroa Soft Paws Cat
Rescue

SPECIES

Feline

BREED

DSH

SEX

Male Intact

AGE

3.1 months

WEIGHT

3.3lbs

INTERPRETED BY

Maggie Machen Lamy,
DVM, DACVIM
(Cardiology)

IMAGING PERFORMED BY

Sammi Fuller, DVM

HOSPITAL NAME

Hart Family Vet Clinic

REFERRING VET

Dr. Fuller

INVOICE

46143

DATE

12/11/25

PRESENTING CLINICAL SIGNS

History: Grade 6/6 heart murmur.

ECHOCARDIOGRAM FINDINGS

2D, m-mode, color flow and doppler imaging is available. The left ventricular wall is normal to decreased in dimension. The LV chamber is mildly increased in diastole. A moderate diameter perimembranous VSD is seen just below the aortic valve. The shunt is left to right; max velocity not recorded. The left atrium is severely dilated. No obvious spontaneous contrast. The right heart is not well visualized; however, no obvious abnormalities are seen. The MPA is difficult to visualize; mild dilation suspected. The mitral valve is normal in structure and mobility with trace MR. No TR. Blood flow through the LVOT is normal in velocity. No AI. Blood flow through the PV is mildly increased in velocity. There is no pleural or pericardial effusion seen.

CARDIAC CHART

FELINE CARDIAC PARAMETERS	BODY WEIGHT (kg)	HR (BPM)	IVSd (cm) <small>(Moise, Pipers)</small>	LVIDd (cm) <small>(Moise, Pipers)</small>	LVWd (cm) <small>(Moise, Pipers)</small>	FS (%)	EF (%)
NORMAL PARAMETER	-----	150-240	0.35-0.55	<2 (mean 1.5)	3.5-0.55	35-67	80-100
PATIENT	1.5		0.32	1.55	0.33	36	60
FELINE CARDIAC PARAMETERS	LA/AO <small>(Boon)</small>	LA/AO HEART BASE (Swe) <small>(Abbott)</small>	LA 2D short axis Base view (cm) <small>(Abbott)</small>		LVOT VEL (m/s)	RVOT VEL (m/s)	E max (m/s)
NORMAL	<1.5	<1.3	<1.2		<1.6	<1.3	<0.9
PATIENT	NM	2.0	1.3		1.1	1.0	NM

**Note: All measurements based upon multi-modal images and methods. An average value is reported.
Adapted from June Boon, Veterinary Echocardiography, 1998
Abbott J & MacLean H JVIM 2006;20: 111-119, Moise et al. Am J Vet Res 47:1476, 1986. Pipers et al. Am J Vet Res 40:882, 1979.*

INTERPRETATION OF THE FINDINGS & FURTHER RECOMMENDATIONS

The cause of the murmur is a perimembranous ventricular septal defect (VSD). The defect is large in dimension, with suspect high velocity left to right flow. There is significant volume overload of the left heart, which is certainly concerning for progression in the future. An ancillary contributing issues is also possible, such as a PDA, although no obvious additional defects are observed. Consider referral in any congenital case for advanced evaluation.

VSDs in cats have variable outcomes, and lifelong monitoring is advised. The defect in this case is certainly hemodynamically significant, leading to severe volume overload at a very young age. There is great concern that this kitty may experience clinical compromise, such as CHF in the near future. The prognosis is guarded to poor long-term. Patient will always remain at risk for development of congestive signs, arrhythmias and/or sudden death in the future.

Given the degree of LA enlargement, you could certainly argue for use of medications in this case. That being said, in a rescue situation, an alternative approach would be to simply monitor for development of clinical signs and consider euthanasia and/or treatment at that time. If elect to medicate, recommendations are as below.



PATIENT

Koroa Soft Paws Cat
Rescue

SPECIES

Feline

BREED

DSH

SEX

Male Intact

AGE

3.1 months

WEIGHT

3.3lbs

INTERPRETED BY

Maggie Machen Lamy,
DVM, DACVIM
(Cardiology)

IMAGING PERFORMED BY

Sammi Fuller, DVM

HOSPITAL NAME

Hart Family Vet Clinic

REFERRING VET

Dr. Fuller

INVOICE

46143

DATE

12/11/25

Monitor at home for any associated clinical signs, including respiratory changes or signs of a thrombus.

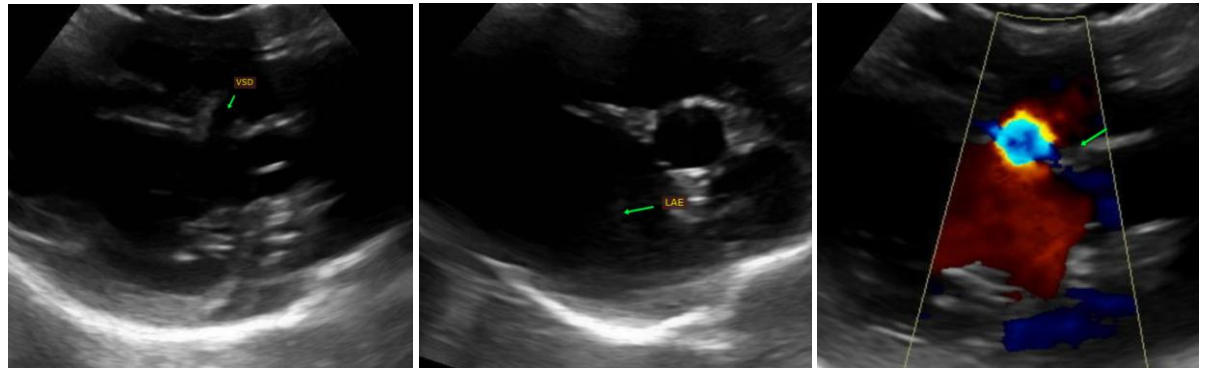
Anesthesia is not advised.

PLAN

Consider referral as discussed. If elect to medicate, compounding may be necessary due to the small size of the patient. Consider Plavix 75mg tabs; Give ¼ tab by mouth every 24 hours (NOTE: bitter along cut edge, may cause foaming at the mouth; coat in entirety). Consider Pimobendan 0.625mg PO q12h. Consider ACE-I 0.5mg/kg PO q12h, pending BP assessment.

Recheck echocardiogram is recommended in 6 months.

IMAGES



The information and recommendations provided are based on the images presented by the referring veterinarian. No evaluation can be communicated regarding pathology that was not visible in the image/video clips provided.

Thank you for this referral. This report was generated using transcription software, and minor dictation errors may be present. If the clinical or image interpretation does not parallel your findings or if I can be of any further assistance, please contact me.

Maggie Machen Lamy, DVM
Diplomate of the American College of Veterinary Internal Medicine (Cardiology)
info@sonopath.com